

Comparative Study of Renal Uptake of some Radiopharmaceuticals in Static and Dynamic Renography

H.I.Abdelkader¹, H.M.Gad², Sahar.Mansour³, Nahla.M.Salatein⁴

Abstract— Renography has been used to measure the renal function for a long time. It is a form of medical imaging of the kidneys that uses radio-labelled pharmaceutical (radiopharmaceuticals). There are different radiopharmaceuticals used in renography such as technetium-99m dimercaptosuccinic acid (Tc-99m DMSA), technetium- 99m diethylenetriamine pentaacetic acid (Tc-99m DTPA), technetium-99m mercaptoacetyltriglycine (Tc-99m MAG3), iodine 131 orthoiodohippurate (OIH) and technetium-99m ethylenedicycysteine (Tc-99m EC). The aim of this study is to compare the split renal function (SRF) measured by Tc-99m DTPA and Tc-99m MAG3 dynamic renography and the renal uptake % measured by Tc-99m DMSA static renal scan. 78 subjects in this study were divided into two groups. Group 1 consists of 25 subjects (14 males and 11 females with age ranging from 3months to 70 years; mean age 54.23 years old) and Group2 consists of 53 subjects (33 males and 20 females with age ranging from 1 to 72 years; mean age 31.17 years old). Both Tc-99m DTPA andTc-99m DMSA renal scintigraphies were performed in Group 1, Tc-99m MAG3 and Tc-99m DMSA renal scintigraphies were performed in Group2. Imagings has been done 2 hours following intravenous injection of 99m Tc-DMSA or immediately after administrations of Tc-99m DTPA andTc-99m MAG3.SRF values calculated by Tc-99m DTPA and Tc-99m MAG3 dynamic renography were statistically compared with renal uptake % values calculated by Tc-99m DMSA static renal scan. The results obtained in Group1 showed that SRF values(mean± sd) % of left and right kidneys measured by Tc-99m DTPA renography were $46.20 \pm 20.39\%$, $53.79 \pm 20.39\%$,respectively and the renal uptake% values (mean± sd)% of left and right kidneys measured by Tc-99m DMSA renal scan were $45.85 \pm 18.81\%$, $54.15 \pm 18.81\%$, respectively. The results obtained in Group2 showed that SRFvalues(mean± sd) of left and right kidneys measured by Tc-99m MAG3 renography were $49.7 \pm 17.72\%$, $50.29 \pm 17.72\%$,respectively and the renal uptake% values(mean± sd)% of left and right kidneys measured by Tc-99m DMSA were $50.09 \pm 17.32\%$, $49.91\% \pm 17.32\%$, respectively . In conclusions the split renal function values measured by Tc-99m DTPA and Tc-99m MAG3 dynamic renography is not statistically different from renal uptake%values measured by Tc-99m DMSA static renal scan ($p=0.737$, $p=0.999$, respectively). A p value less than .05 was considered significant. Also the results showed that Tc-99m DMSA is more agreed withTc-99m MAG3 than Tc-99m DTPA, so Tc -99m MAG3 is preferred as it gives better information about both the structure of renal parenchyma and kidney functions. SRF values obtained from MAG3 and DTPA radiopharmaceuticals are reliable although that DMSA is considered as the most reliable radiopharmaceutical used in the measurements of renal uptake. So it is possible to use one of these techniques for determination of split renal function or renal uptake.

Index Terms—split renal function, renal uptake%, Tc-99m DMSA, Tc-99m DTPA, Tc-99m MAG3.

1 INTRODUCTION

Renal studies using radiopharmaceuticals (renography) have been used for a long time to estimate renal functions [1], [2]. This made renal scintigraphy to be one of the most useful tools in nuclear medicine [3], [4].Renography can be performed using different radiopharmaceuticals such as technetium-99m dimercaptosuccinic acid (^{99m}- Tc DMSA), technetium- 99m diethylenetriamine pentaacetic acids (^{99m} TcDTPA), technetium- (^{99m} mercaptoacetyltriglycine (^{99m}-Tc MAG3), iodine 131orthoiodohippurate(OIH)andtechnetium-99m ethylenedicycysteine (^{99m}-Tc EC) [5].

Renal functions such as split renal function (SRF), differential renal function and relative renal function can be expressed as a percent of total renal function [2]. ^{99m}-Tc DMSA, Tc-99m

DTPA and ^{99m}-Tc MAG3 have different renal uptakes mechanisms, so they can be used to compare the relative renal uptakes [6].The quantification of renal uptake with radionuclide studies is simple and non invasive way to assess renal function [7]. ^{99m}-Tc DMSA was introduced in the early 1970 [8],[9].Ever since, ^{99m}-Tc DMSA as static renal radiopharmaceutical is considered the most reliable method used in measuring parenchymal function of the kidneys, pyelonephritis, renal scarring and functional renal mass[10], [11] ,[12], [13]. And also calculating differential, individual and absolute renal function [14], [15]. Tc-99m DMSA has been the most appropriate tracer for high resolution imaging of renal cortex [16]. Tc-99m DTPA is a radiopharmaceutical that is freely filterable at the glomerulus.It is used for measuring glomerular filtration rate (GFR) for each kidney [17] and also can be used to measure total and individual renal function [2] using the gamma camera technique. ^{99m}-Tc MAG3 is a tubular excreted radiopharmaceutical that is used for measuring effective renal

(1) Ass.Prof.-Physics Department, Faculty of Science, Mansoura University

(2) Prof and chairman of radiology dept/Urology and Nephrology Centre, Faculty of Medicine, Mansoura University

(3) Ph.D /Urology and Nephrology Centre, Mansoura University

(4) M.Sc. research student Physics Department, Faculty of Science, Mansoura University

plasma flow (ERPF) for each kidney and also can be used for measuring kidney functions using gamma camera [2], [6]. Tc-99m EC radiopharmaceutical has been developed to perform dynamic renography and to measure relative renal function [18]. This study aimed to compare the split renal function values calculated from ^{99m}Tc DTPA and Tc-99m MAG3 dynamic renography with the renal uptake values calculated from ^{99m}Tc DMSA static renography .

2 SUBJECT AND METHOD

This study include 78 subjects (47males and 31 females) ranging in age from 3 months to 72 years who were referred to the urology and nephrology centre at Mansoura University for routine indications, such as estimation of renal functions and pathophysiology, etc during 2014 to 2016. A total 78 subjects were divided into two separate groups Group 1 consists of 25 subjects (14 males and 11 females; mean age 54.23 years old) who done dynamic renography using ^{99m}Tc DTPA and static renal scan using ^{99m}Tc DMSA. Group 2 consists of 53 subjects (33males and 20females; mean age 31.17 years old) who done both the dynamic renography using ^{99m}Tc MAG3 and the static renal scan with ^{99m}Tc DMSA. In all cases of the two groups, there are a variety of clinical diagnoses such as hydronephrosis, pyelonephritis, kidney obstruction, polycystic kidney, pyelonephritic with hydronephrosis and reduced renal function. Both dynamic and static renal images were acquired with the patients in a supine position to minimize renal depth and reduce movement. and with gamma camera's detector placed in posterior view; ideally the renal area should be in the center of the field of view. All studies were done using an BRIGHT VIEW (PHILIPS) gamma camera attached to a monitor PHILIPS computer with double head detector, low energy, high resolution and parallel hole collimator.

All information about patient such as weight, height, age and clinical information was recorded. The patients were hydrated with 500ml of water 20-30 min prior to radiopharmaceuticals injection then the bladder emptied before examination. ^{99m}Tc DMSA static renography with was carried out on all patients. In ^{99m}Tc DMSA static renal scan, patients were injected intravenously with dosage ranging from 0.5-3mCi and static images were acquired 2 hour following tracer administration at the anterior, posterior and posterior oblique projections then the renal uptake % values were calculated. Poor renal absorption of ^{99m}Tc DMSA may be observed on some patients with advanced renal failure. it is reported that an image at sufficient level can be obtained in delayed time up of 24 hours on these patients. Dynamic renography with ^{99m}Tc DTPA and ^{99m}Tc MAG3 was carried out on 25, 53 patients respectively. In dynamic renography using ^{99m}Tc DTPA and ^{99m}Tc MAG3, patients were injected intravenously of dosage ranging from 0.5-5mCi and furosemide was given 3 minutes following tracer administration, the dose of furosemide was 0.5 mg/kg body weight. Dynamic imaging was performed within 20 minutes in the

posterior projection.

3 RESULTS

The results of the renal uptakes for 78 patients classified into two separate groups were calculated and compared by the Statistical package for the social sciences, version 20 (SPSS software). The results of the average split renal function and standard deviation values for right and left kidneys obtained from ^{99m}Tc DTPA and ^{99m}Tc MAG3 dynamic renography were compared with the average renal uptakes and standard deviation values for right and left kidneys obtained from ^{99m}Tc DMSA static renal scan.

The results are tabulated in table 1 and 2.

Two examples for two cases who done both dynamic renography and static renal scan were illustrated in figure 1(a, b) and figure 2(a, b).

Figure 1(a, b) shows the case that made both dynamic renography with ^{99m}Tc DTPA and static renal scan with ^{99m}Tc DMSA respectively.

Figure 2(a, b) shows the case that made both dynamic renography with ^{99m}Tc MAG3 and static renal scan with ^{99m}Tc DMSA respectively.

Table 1 .the mean split renal function values obtained from ^{99m}Tc DTPA and the mean split uptakes values obtained from ^{99m}Tc DMSA.

Method	Left kidney		right kidney	
	Mean ± SD	%	Mean ± SD	%
^{99m} Tc DMSA	45.85	±18.81	54.15	±18.81
^{99m} Tc DTPA	46.20	±20.39	53.79	±20.39

Table 2 .the mean split renal function values obtained from ^{99m}Tc MAG3 and the mean uptakes values obtained from ^{99m}Tc DMSA .

Method	Left kidney		right kidney	
	Mean ± SD	%	Mean ± SD	%
^{99m} Tc DMSA	50.09	±17.32	49.91	±17.32
^{99m} Tc MAG3	49.7	±17.72	50.29	±17.72

There was no statistically significant difference between the split renal function values measured with either ^{99m}Tc DTPA or ^{99m}Tc MAG3 dynamic renography and the renal uptakes values obtained from ^{99m}Tc DMSA static renal scan. (p=0.737, p=0.999, respectively) .

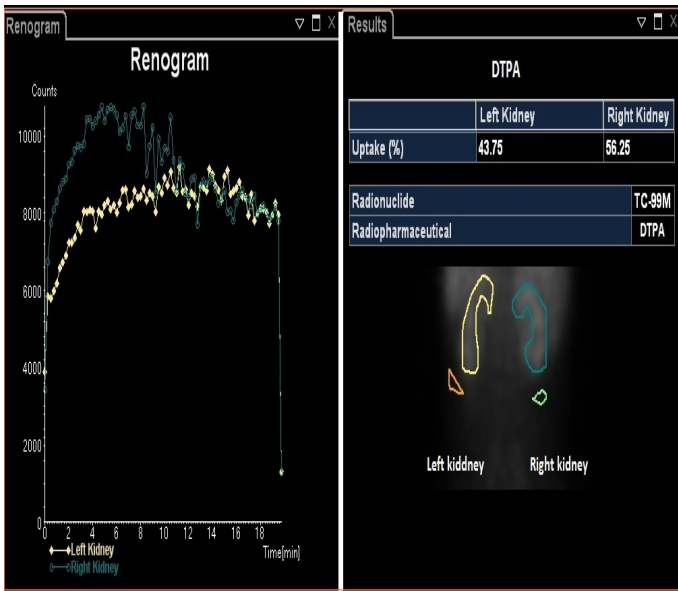


Figure 1(a)

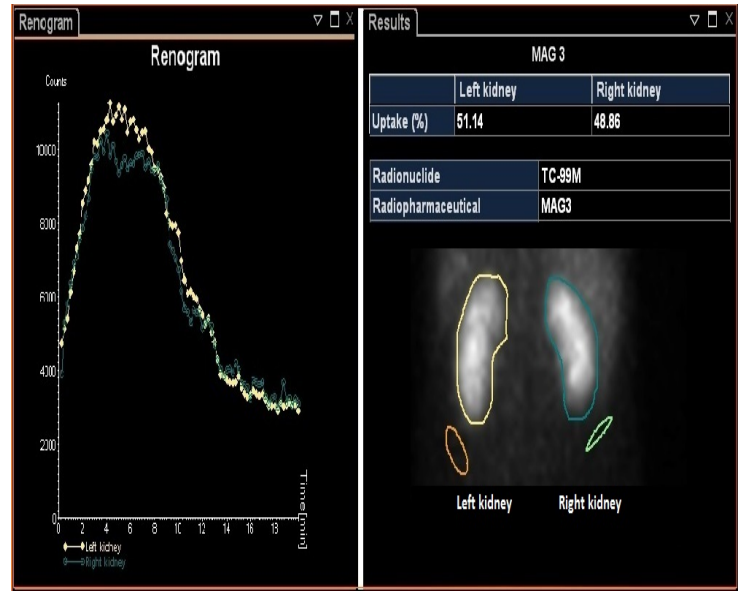


Figure 2(a)

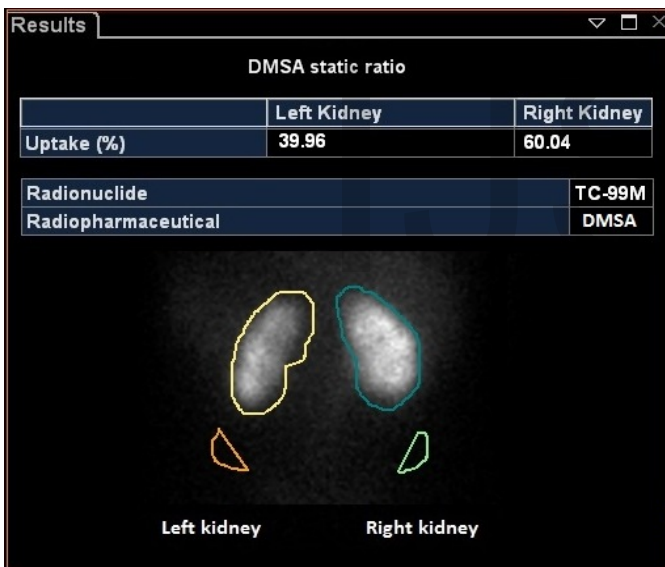


Figure 1(b)

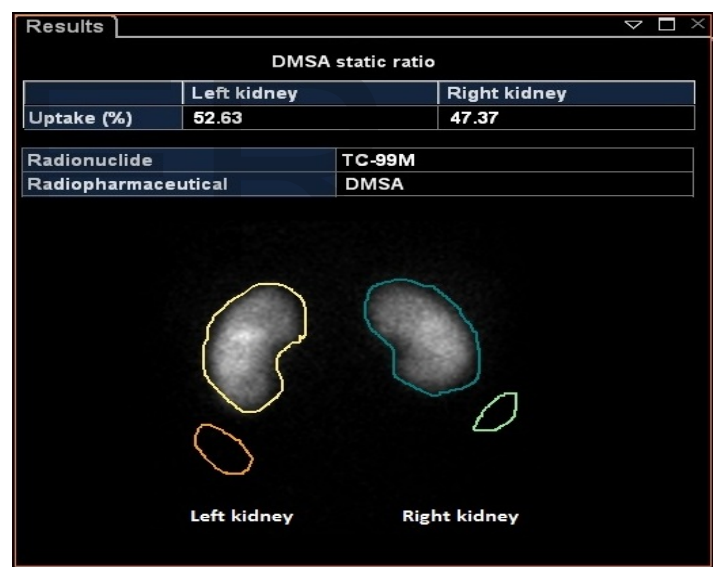


Figure 2(b)

Figure 1(a, b) show both dynamic renography with Tc-99m DTPA and static renal scan with ^{99m}Tc DMSA respectively for one of the cases.

Figure 2(a, b) show both dynamic renography with Tc-99m MAG3 and static renal scan with ^{99m}Tc DMSA respectively for one of the cases.

4 Discussion

There are more radiopharmaceuticals that can be used in renography such as Tc-99m DMSA for static (cortical) renography and ^{99m}Tc DTPA, Tc-99m MAG3, ^{99m}Tc EC and iodine 131 orthoiodohippurate for dynamic renography. [5] ^{99m}Tc DMSA is used for scintigraphic diagnosis of the following renal disorders by nuclear medicine specialists; morphological analysis of renal cortex, analysis of each renal function, ectopic renal location.

^{99m}Tc DMSA static renography has been considered the best method for estimation SRF because ^{99m}Tc DMSA enters the proximal tubular cell and is largely bound to serum protein which makes enough long time to allow static imaging of tubular activity over several minutes. [2], [15], [19]

Parenchymal function of the kidneys can be determined by using ^{99m}Tc DMSA static renography, both quantitatively and visually and also absolute and differential renal function can be calculated. [14], [15]

These functions can also be estimated by means of dynamic renography as well as ^{99m}Tc DMSA static renography. Dynamic imaging with ^{99m}Tc DTPA or ^{99m}Tc MAG3 which has been taken in the first several minutes usually takes 20 to 30 min and reflects differential renal function parameter (uptake). [20], [21] ^{99m}Tc DTPA and ^{99m}Tc MAG3 are used for examinations of kidneys by dynamic scintigraphy, quantitative determination of tubular extraction rate and for separated examinations of function of one kidney.

In the previous studies, there is no clinical significant difference between differential function values obtained from ^{99m}Tc DMSA and ^{99m}Tc MAG3 renal scintigraphy. Also the studies showed that ^{99m}Tc MAG3 is able to detect parenchymal damage [22], [23]. Another study showed that there is a high correlation between ^{99m}Tc EC and ^{99m}Tc DMSA renal scintigraphy in terms of relative renal function. [24], [25]

Domigues et al. (2006) compared relative renal function values calculated by either ^{99m}Tc EC or ^{99m}Tc DTPA dynamic renography with that calculated by ^{99m}Tc DMSA static renography. They noticed significant difference between ^{99m}Tc DTPA and ^{99m}Tc DMSA renal scintigraphy and no statistically difference between ^{99m}Tc EC and ^{99m}Tc DMSA renal scintigraphy. [26]

In an experimental study in rabbits, renal function values using ^{99m}Tc DTPA and ^{99m}Tc MAG3 dynamic renal scintigraphy were compared to those obtained using ^{99m}Tc DMSA static renal scintigraphy. There was no significant difference between these methods and it was confirmed that ^{99m}Tc DMSA renography can be replaced by ^{99m}Tc DTPA or ^{99m}Tc MAG3 renography to determine differential renal function. [6]

In another study, Dostbil et al. (2011) found that SRF values estimated by ^{99m}Tc DTPA and ^{99m}Tc MAG3 dynamic renal scintigraphy were not statistically different with that values obtained by ^{99m}Tc DMSA static renal scintigraphy. [2]

In another study, ^{99m}Tc DTPA and ^{99m}Tc MAG3 renal scintigraphy were compared with ^{99m}Tc DMSA renal scintigraphy in terms of DRF, this study showed that there is no significant difference between these methods. [27] In our study, re-

nal uptakes of ^{99m}Tc DTPA, ^{99m}Tc MAG3 and ^{99m}Tc DMSA radiopharmaceuticals were compared and results showed that there is no statistical difference.

5 CONCLUSION

The split renal function values measured by ^{99m}Tc DTPA and ^{99m}Tc MAG3 dynamic renography is not statistically different from renal uptake % values measured by ^{99m}Tc DMSA static renal scan ($p=0.737$, $p=0.999$, respectively). A p value less than .05 was considered significant. Also the results showed that ^{99m}Tc DMSA is more agreed with ^{99m}Tc MAG3 than ^{99m}Tc DTPA, so ^{99m}Tc MAG3 is preferred as it gives better information about both the structure of renal parenchyma and kidney functions. SRF values obtained from MAG3 and DTPA radiopharmaceuticals are reliable although that DMSA is considered as the most reliable radiopharmaceutical used in the measurements of renal uptake. So it is possible to use one of these techniques for determination of split renal function or renal uptake.

REFERENCES

- [1] Lima. MCL et.al. Estimation of absolute renal uptake with technetium-99m dimercaptosuccinic acid: direct comparison with the radioactivity of nephrectomy specimens. Sao Paulo Med J. 2008; 126(3):150-5.
- [2] Dostbil .Z et.al. Comparison of split renal function measured by Tc-99m DTPA, Tc-99m MAG3 and Tc-99m DMSA renal scintigraphies in paediatric age groups. Clinical Reviews and Opinions Vol. 3(2), pp. 20-25, February 2011.
- [3] Handmaker H, Young BW and Lowenstein JM: Clinical experience with Tc-99m DMSA (dimercaptosuccinic acid), a new renal-imaging agent. J Nucl Med 16: 28-32, 1975.
- [4] Russell CD, Thorstad BL, Stutzman ME, Yester MV, Fowler D and Dubovsky EV: The kidney; imaging with Tc-99m mercaptoacetyltri-glycine, a technetium-labeled analog of iodohippurate. Radiol 172: 427-430, 1989.
- [5] Moran JK (1999). Technetium-99m-EC and other potential new agents in renal nuclear medicine. Semin. Nucl. Med., 29: 91-101.
- [6] Lee WG, Kim JH, Kim JM, Shim KM, Kang SS, Chae HI, et al. Renal uptakes of Tc-99m MAG3, Tc-99m DTPA, and Tc-99m DMSA in rabbits with unilateral ureteral obstruction. In Vivo. 2010; 24:137-139.
- [7] E.Tsukamoto. Validity of Tc-99m DMSA renal uptake by planar posterior-view method in children. Annals of nuclear medicine Vol.13, No.6, 383-387, 1999.
- [8] Lin TH, Khentigan A, Winchell HS. A Tc-99m chelate substitute for organoradiomercurial renal agents. J Nucl Med. 1974; 15(1):34-5. 2.
- [9] Müller-Suur R, Magnusson G, Bois-Svensson I, Jansson B. Estimation of technetium 99m mercaptoacetyltri-glycine plasma clearance by use of one single plasma sample. Eur J Nucl Med. 1991; 18(1):28-31. 3.
- [10] Ardelá Diaz E, Miguel Martínez B, Gutiérrez Duenas JM, Díez Pascual R, García Arcal D, Domínguez Vallejillo FJ: Comparative study of differential renal function by DMSA and MAG-3 in congenital unilateral uropathies. Cir Pediatr. 2002; 15: 118-21.
- [11] Piepsz A: Cortical scintigraphy and urinary tract infection in chil-

- dren. *Nephrol Dial Transplant*. 2002; 17: 560-2.
- [12] Piepsz A, Colarinha P, Gordon I, et al. Guidelines for Tc-99m DMSA scintigraphy in children. *Eur J Nucl Med*. 2001; 28:BP37-BP41.
- [13] Arnold RW, Subramanian G, McAfee JG, Blair RJ, Thomas FD. Comparison of Tc-99m complexes for renal imaging. *J Nucl Med*. 1975; 16:357-367.
- [14] Suur RM, Gutsch HU. Tubular reabsorption of Technetium- 99m-DMSA. *J Nucl Med*. 1995; 36:1654-1658.
- [15] De Lange MJ, Piers DA, Kosterink JG, van Luijk WH, Meijer S, de Zeeuw D, et al. Renal handling of technetium-99m DMSA: evidence for glomerular filtration and peritubular uptake. *J Nucl Med*. 1989; 30:1219-1223.
- [16] Taylor A. Radiopharmaceuticals for the measurement of 'functional renal mass'. In: Blaurock MD, editor. Evaluation of renal function and disease with radionuclides: the upper urinary tract. Basel: Karger; 1989. p. 60-83.
- [17] Itoh K (2001). Tc-99m MAG3: review of pharmacokinetics, clinical application to renal diseases and quantification of renal function. *Ann. Nucl. Med.*, 15: 179-90.
- [18] Domingues F. C et.al. Comparison of Relative Renal Function Measured with Either Tc-99m DTPA or Tc-99m EC Dynamic Scintigraphies with that Measured with 99mTc-DMSA Static Scintigraphy. *Int Braz J Urol*. 2006; 32: 405-9
- [19] Summerlin AL, Lockhart ME, Strang AM, Kolettis PN, Fineberg NS, Smith JK (2008). Determination of split renal function by 3D reconstruction of CT angiograms: a comparison with gamma camera renography. *AJR Am. J. Roentgenol.*, 191: 1552-1558.
- [20] Bannister KM, Penglis S, Bellen JC, Baker RJ and Chatterton BE: Kit preparation of technetium-99m-mercaptoacetyltriglycine: analysis, biodistribution and comparison with technetium-99m- DTPA in patients with impaired renal function. *J Nucl Med* 31: 1568-1573, 1990.
- [21] Lipowska M, He H, Malveaux E, Xu X, Marzilli LG and Taylor A: First evaluation of a 99mTc-tricarboxyl complex, 99mTc(CO)₃(LAN), as a new renal radiopharmaceutical in humans. *J Nucl Med* 47: 1032-1040, 2006.
- [22] Ritchie G, Wilkinson AG, Prescott RJ (2008). Comparison of differential renal function using technetium-99m mercaptoacetyltriglycine (MAG3) and technetium-99m dimercaptosuccinic acid (DMSA) renography in a paediatric population. *Pediatr. Radiol*. 38: 857-862.
- [23] Gordon I, Anderson PJ, Lythgoe MF, Orton M. Can Technetium-99m-Mercaptoacetyltriglycine replace Technetium-99m- Dimercaptosuccinic acid in the exclusion of a focal renal defect? *J Nucl Med*. 1992; 33:2090-2093.
- [24] Atasever T, Ozkaya O, Abamor E, Soylemezoglu O, Buyan N, Unlu M: 99mTc ethylene dicysteine scintigraphy for diagnosing cortical defects in acute pyelonephritis: a comparative study with 99mTc dimercaptosuccinic acid. *Nucl Med Commun*. 2004; 25: 967-70.
- [25] Kibar M, Yapar Z, Noyan A, Anarat A: Technetium- 99m-N,N-ethylenedicysteine and Tc-99m DMSA scintigraphy in the evaluation of renal parenchymal abnormalities in children. *Ann Nucl Med*. 2003; 17: 219-25.
- [26] Domigues FC, Fujikawa GY, Decker H, Alonso G, Pereria JC, Duarte PS. Comparison of relative renal function measured with either Tc-99m- DTPA or Tc-99m-EC dynamic scintigraphies with that measured with Tc-99m- DMSA static scintigraphy. *International Braz J Urol*. 2006; 32:405-409.
- [27] Demirel BB, Balci TA, Tasdemir B, Koc ZP. Comparison of DTPA and MAG3 renal scintigraphies in terms of differential renal function based on DMSA renal scintigraphy. *Pak J Med Sci* 2012; 28(5): 795-799